

Corneal Topographic Patterns in Healthy Eyes in a Sample of Iraqi Population Using Pentacam

Roa Khalid Abdulhassan, Al-Qadisiyah University College of Medicine (AQUCOM); Email: rora07810522033@gmail.com; Mobile: +9647707504334

ORCID: <http://orcid.org/0000-0002-2900-3630>

Furkaan Majied Hamied, Al-Qadisiyah University College of Medicine (AQUCOM)

Email: furqan.majied@qu.edu.iq; Mobile: +9647509606001.

ORCID: <http://orcid.org/0000-0003-2325-4428>.

Correspondence author: Roaa Khalid Abdulhassan, Al-Qadisiyah University College of Medicine (AQUCOM); Email: rora07810522033@gmail.com;

Mobile: +9647707504334, ORCID: <http://orcid.org/0000-0002-2900-3630>

Received: 11/10/2021 Accepted: 12/12/2021 Published: January, 2022

Abstract

Background: Corneal topography is computer assisted diagnostic tool, used to characterize the shape of cornea . Originally, topographic map was only used to describe the anterior corneal surface, devices as Pentacam now are able to characterize both anterior and posterior corneal surfaces, creating three dimensional map. It's essential in determining the quality of vision and the state of cornea and assess diseased from normal cornea.

Aim: The purpose of this study is to determine the distribution of corneal topographic patterns in Iraq, to make a corneal topographic database of our local people.

Subjects and methods: Five hundred and twenty healthy eyes of two hundred and sixty subjects coming to Ibn AL-Haitham Teaching Eye Hospital at Baghdad, Iraq, selected to be included in the study, (134) males and (126) females with age range of 18-60years. Data collection conducted between May 2018 and March 2019. Sample randomly selected and determine inclusion and exclusion criteria for each subject, proper history taking from all, then do corneal topography using Pentacam (oculus) for each eye in the included subjects after complete ophthalmological examination (Best corrected visual acuity, refractive error, Intraocular pressure measurement, slit lamp examination, Break up time and fundoscopic examination).

Results: Analysis of data was carried out using the available statistical package of SPSS-25, we analyzed (520) healthy eyes of (260) subjects. Abnormal patterns (Asymmetrical bowtie, irregular) were seen in (23.6_36.5 %) of people and normal patterns (Symmetrical bowtie, round, oval) were seen in (63.5_76.4%) of people. There was statistical difference toward older age group (≥ 40 years), that is to mean significant difference with age; also there was significant difference with gender with females highest proportion for most of the patterns. Patterns not affected by laterality (between right and left eye).

Conclusion: Elderly persons tend to have more change in topographic mapping and affect pattern of corneal topography, due to physiological aging process involve corneal surface curvature, than that in younger population, so there is significant difference with aging. Also gender affects topographic patterns with female's highest proportion for most of the patterns. Also we conclude that the patterns not affected by laterality. By using Pentacam (Oculus) for healthy eyes in Iraqi sample of 260 participants found that normal patterns about 75.4% and abnormal patterns about 23.6%, that's to mean 1 out of 4 subjects with healthy eyes have abnormal topographic pattern.

Keywords: Corneal topographic patterns; cross-sectional study; Pentacam.

Introduction

The cornea is a transparent tissue with significant refractive and barrier functions. The main function of the cornea is optical; it forms the principal refractive surface, accounting for some 70% (40-45 diopters) of the total refractive power. The cornea is basically transparent to visible light because its internal structures are tuned to the size of a fraction of the wavelengths of visible light the fibers are spaced closer than half a wavelength of visible light apart and the fibers in each of the major layers are arranged in an orderly manner. [2] The cornea appears elliptical when viewed from the front. In adults, it measures about 12 mm in the horizontal meridian and about 11 mm in the vertical. From behind, when the cornea is viewed at its posterior landmark, its circumference appears circular. The cornea is approximately 1 mm thick at its periphery and 0.5 mm thick centrally. [3] In its central third, the optical zone, the radius of curvature of the anterior surface is about 7.8 mm and that of the posterior 6.5 mm, in adult [2,3].

Corneal topography allows qualitative and quantitative measurement of corneal curvature [4,5]. The first advancement in assessing the shape of the anterior corneal surface was made in the late 1800s with the development of the Placido disc [6-8]. A second technique for corneal topographic assessment is the scanning slit technique (*e.g.*, Orbscan). This method uses rapidly scanning projected slit beams of light and a camera to capture the reflected beams to create a map of the anterior and posterior corneal surface [7-9]. A third technique, known as Scheimpflug imaging, this concept was first described by Jules Carpentier in 1901, having been cited and credited in the original patent by Theodor Scheimpflug in 1904. Another development among ophthalmic camera systems based on Scheimpflug principle is the Pentacam (Oculus, Wetzlar, Germany) [10], The light source consist of UV-free blue light emitting diode (LED's) with wavelength of 475nm [11], As measured by keratometry the average anterior radius of curvature 7.2- 8.4 mm in Caucasians, and steeper in Asiatics. The cornea is flatter in men than in women, the corneal curvature varies from apex to limbus. There is greater flattening nasally than temporally, and above than below. The apical radius of the posterior corneal surface is 5.8 mm [2].

Normal corneal topography—specifically the anterior sagittal curvature map—can take one of the following patterns: Regular: normal topographic corneal image without

astigmatism demonstrates a relatively uniform color pattern centrally with a natural flattening in periphery [12]. A round pattern, Oval, Bow tie: This pattern is further classified as symmetric bow tie (SB), asymmetric bow tie (AB) [13-16]. And irregular pattern [12]. This classification scheme was further expanded, five additional categories to enable classification of asymmetric corneal topographic patterns in normal corneas : bow tie(symmetrical or asymmetrical) with skewed radial axis (SB/SRAX) or (AB/SRAX) respectively, asymmetric bow tie with superior steepening (AB/SS) , asymmetric bow tie with inferior steepening (AB/IS), Superior steepening and inferior steepening (Fig 1) [4,13] SRAX Angulations is considered clinically significant when it exceeds 22° . AB/SS It is risky when the difference between two symmetric points on the 4 mm central circle is more than 2.5 D. AB/IS If the difference between symmetric values on the 4 mm central circle is more than 1.5 D, it is considered significant and risky [17].

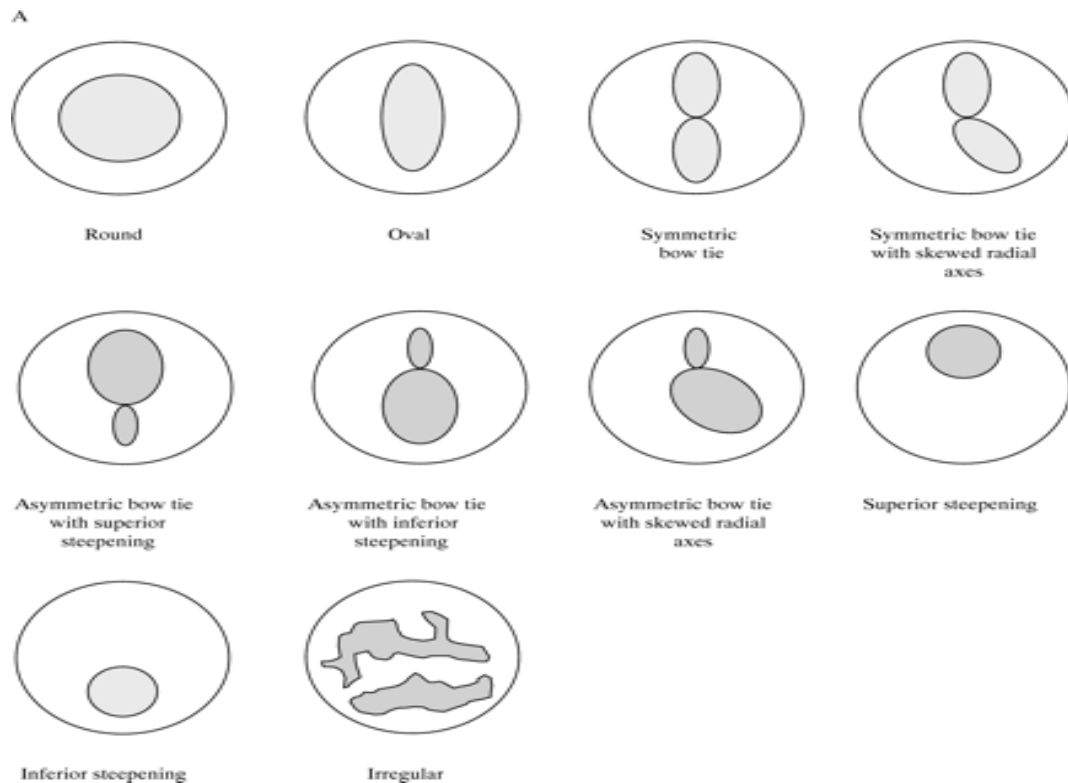


Figure 1. Classification of corneal topographic patterns [13].

Subjects and methods:

This is a descriptive cross sectional study carried out in Ibn AL-Haitham Teaching Eye Hospital at Baghdad, Iraq. Data collection conducted between May 2018 and March 2019. According sample size equation, five hundred and twenty healthy eyes of two hundred and sixty subjects coming to the institute, selected to be included in the study,

(134) males and (126) females with age range of 18-60 years. Subjects attended outpatient department, randomly selected. The included subjects were: Age range between (18-60) year, BCVA 6/6 using snellen's chart to allow adequate fixation, Refractive error: myopia and hyperopia and astigmatism less than (2 diopters), Break up time (BUT) > (10 seconds), No previous ocular surgery and No previous ocular trauma.

Healthy subjects were enrolled. After proper history taking both medical and ophthalmological, clinical examinations done for each one of them including BCVA, refractive error, IOP measurement, slit lamp examination, BUT done for all of them to assess stability of the tear film by using fluorescein strip instilled into lower fornix of conjunctival sac and ask the subjects to blink several times and wait for appearance of first black spot, this test repeated several time and the time recorded. Then fundoscopic examination. Then corneal topography taken using one device pentacam (oculus) for all subjects with same settings by using sagittal map and the anatomical axis which is the real reference axis and the central (4mm) zone of cornea, and the result obtained by the same operator (to reduce chance of inter individual variation of results). Artifact in the Pentacam often displayed in the square of "QS" as comments marked with yellow or red colors, in such cases re-captured image. Sagittal curvature of cornea displayed using color coded map repeated three times for each eye, both eyes were examined and determine corneal topographic patterns for each eye.

Result

Two hundred and sixty participants (total 520 eyes examined) were enrolled in this study with a mean age of 39.5 ± 13.1 ranging from 18 to 60 years. Males represent 51.5% while females represent 48.5% of the studied group, Table.1. Shows the age distribution by sex for the studied participants.

Table 1. The age and gender distribution of the studied group (n=260).

		No	%
Age (years)	<20y	20	7.7
	20---29	52	20.0
	29---39	44	16.9
	39---49	70	26.9
		Gender	
	49---59	60	23.1
	≥60years	14	5.4
	Mean ± SD (Range)	39.5±13.1 (18-60)	
	Male	134	51.5
	Female	126	48.5

There is no statistical significance in patterns for right and left eyes ($P=0.980$) when estimating each pattern *per se*, with highest proportion for regular pattern (26.2%) for right and (23.1%) for left eye with total (24.6%) from 520 eyes. When categorizing the pattern as normal (SB, round and oval) and abnormal (AB and irregular), the topographic patterns showed also a non-significant difference between right and left eyes ($P=0.444$) with highest proportion for normal (71.5%) in the right eye and 68.5% for the left eye giving an impression of that pattern is not significantly affected by laterality, Table.2.

Table .2. The pattern distribution of the total 520 eyes examined.(n=520).

		Eye				P value
		RT		LT		
		No	%	No	%	
Topographic patterns	AB / IS	12	4.6	14	5.4	0.980
	AB / SRAX	2	0.8	2	0.8	
	AB / SS	20	7.7	20	7.7	
	SB	36	13.8	36	13.8	
	SB / SRAX	6	2.3	8	3.1	
	SS	32	12.3	28	10.8	
	IS	6	2.3	6	2.3	
	Oval	4	1.5	8	3.1	
	Round	40	15.4	38	14.6	
	Regular	68	26.2	60	23.1	
	Irregular	34	13.1	40	15.4	
Topographic patterns	Abnormal (AB, Irregular)	74	28.5	82	31.5	0.444
	Normal (SB, Oval, Round)	186	71.5	178	68.5	

***Significant difference between proportions using Pearson Chi-square test at 0.05 level.**

Further cross-tabulation of topographic patterns across different age groups, as categorized by decades, revealed statistically significant difference ($P=0.0001$) in pattern distribution by age groups, with highest proportion toward older age group (≥ 40 years) for most of the patterns except for regular, SB, IS, in which highest proportion were in age group (30-39 years), but when comparing normal versus abnormal patterns, the highest proportion for normal in all age group, but with decrease the proportion between normal and abnormal in ≥ 40 year. Finally, the results demonstrate the pattern affected as normal and abnormal by age group with more abnormal in the older age group (≥ 40 years) than young, Table. 3.

Table .4 shows the comparison of pattern in both genders with a significant difference (highest proportion in females) for all patterns ($P < 0.05$), except for some patterns as SB, round, and regular which were high in males than in females. Concerning the comparison by normal and abnormal patterns for both genders there is also a significant difference but with decrease proportion between normal and abnormal in females (76.1% versus 23.9%) for males and (63.5% versus 36.5%) for females ($P < 0.05$). Another relation was noted in pattern affected by gender and as more abnormal patterns in females than in males.

Table .3. The comparison of topographic patterns by age (n=260).

		Age (years)						P value
		<30y		30----39		≥40years		
		No	%	No	%	No	%	
Topographic patterns	AB / IS	4	2.8	4	4.5	18	6.3	0.0001*
	AB / SRAX	4	2.8	-	-	-	-	
	AB / SS	8	5.6	8	9.1	24	8.3	
	SB	26	18.1	20	22.7	26	9.0	
	SB / SRAX	-	-	-	-	14	4.9	
	SS	6	4.2	8	9.1	46	16.0	
	IS	4	2.8	4	4.5	4	1.4	
	Oval	2	1.4	-	-	10	3.5	
	Round	34	23.6	-	-	44	15.3	
	Regular	42	29.2	34	38.6	52	18.1	
	Irregular	14	9.7	10	11.4	50	17.4	
Topographic patterns	Abnormal (AB, Irreg)	34	23.6	26	29.5	96	33.3	0.115
	Normal (SB, Oval, Round)	110	76.4	62	70.5	192	66.7	

*Significant difference between proportions using Pearson Chi-square test at 0.05 level.

Discussion

In this study we found that pattern not affected by laterality, this is in agreement with the finding of all comparable studies Bogan et al [5], America; Hashemi H et al [9], Iran; Kim et al [16], Korea and Jehangir et al [18], Pakistan. This is may be due to fact that intrinsic and extrinsic circumstances are the same. Comparison of topographic patterns on basis of age ,and we found that highest proportion toward older age group (≥ 40 years) specially for (irregular 17.4%), (SS 16.0%), (round 15.3%), (SB/SRAX 4.9%) and (oval 3.5%). This means a significant difference with age, while (regular 38.6 %) and (SB 22.7%) highest proportion in younger age group (30- 39 years), this is in agreement with the finding of Hashemi et al [9] and in contrast to other studies [5,16,19]. The findings variation may be due different range of refractive error

included in Bogan et al [5] study (emmetropic and ametropic people with refractive error range from +5.5 to -8.37D included in the study) and Kim et al [16] study (up to -16 D included in the study). Additionally, may be due to a wide variety of age group in Korean study (8-79 years), and small sample size included in Jehangir et al [18] study. These results suggest that cornea of elderly people affected by anatomical and functional changes that normally occurred with aging as changing from with rule to against the rule and steepening of curvature [19], so will be more change in topographic patterns than younger.

Table.4. The comparison of topographic patterns by gender (n= 260).

		Gender				P value
		Male		Female		
		No	%	No	%	
Topographic patterns	AB / IS	10	3.7	16	6.3	0.0001*
	AB / SRAX	-	-	4	1.6	
	AB / SS	12	4.5	28	11.1	
	SB	44	16.4	28	11.1	
	SB / SRAX	2	0.7	12	4.8	
	SS	32	11.9	28	11.1	
	IS	2	0.7	10	4.0	
	Oval	6	2.2	6	2.4	
	Round	44	16.4	34	13.5	
	Regular	76	28.4	52	20.6	
Irregular	40	14.9	34	13.5		
Topographic patterns	Abnormal (AB, Irreg)	64	23.9	92	36.5	0.002*
	Normal (SB, Oval, Round)	204	76.1	160	63.5	

*Significant difference between proportions using Pearson Chi-square test at 0.05 level.

Comparison topographic patterns on basis of gender, in this study we found significant difference with highest proportion in females for most of patterns. These results in contrast to Bogan et al [5], Kim et al [16] and Jehangir et al [18] as their results not significant for patterns on basis of gender, while Hashemi et al [9] study results is borderline non-significant ($p = 0.087$). Such results may be due to different age distribution of the studied individual was an underlying cause of the difference observed between males and females. This study showed normal topographic patterns ranged from (63.5-76.4 %) and abnormal topographic patterns range from (23.6- 36.5%), these results comparable to American studies [5,20] in which normal topographic patterns are (61% and 80% respectively) and disagree and be much different from that of Jehangir et al [18] in which abnormal topographic patterns range from (77 -79%) and normal patterns (21-23%). Also differ from the Korean study [16] in which about (38% are normal

topographic patterns and 61% are abnormal patterns). High percent of abnormal topographic patterns in mentioned last two studies [18, 16] may be due to tear film abnormalities mostly dry eyes that affect topographic patterns when compare their studies to American studies [5,20]. The etiology of high percent of normal patterns as explained by Bogan et al [5] and Liu et al [20], they instilled artificial tears into every eye examined prior to topographic examination, thus avoiding dryness of cornea that largely affect topographic map results. While in this study the results show high percent of normal patterns as we exclude the dry eyes and tear film abnormalities from the study. We found variability in distribution of topographic patterns between all mentioned studies in addition to our study this may be due to a number of variables between studies one of these different machine involved in each study to perform topographic examination, video keratograph used by Bogan et al [5] as well as Kim et al [16], orbscan used by Liu et al [20] and Hashemi et al [9], SHIN NIPPON CT 1000 (placido disc) used by Jehangir et al [18], while we used pentacam (oculus, b Schwind). Other factor affect patterns between us and other mentioned studies is different range of refractive error included in each study Bogan et al [5] both emmetropic and ametropic participants involved in study with range of refractive error from + 5.5 to -8.37 D. Liu et al [20] included participants with refractive error less than -6.0 D of myopia and astigmatism of less than 2 D in the study, Korean study by Kim et al [16] up to -16.0 D included in their study, while Jehangir et al [18] included participants with up to 5 D of myopia, hyperopia and astigmatism. The present study included refractive error up to 2 D of myopia, hyperopia and astigmatism. Also unequal randomly selected participants and unequal distribution of age and sex affect patterns distribution. So a number of factors affect topographic patterns of corneal map.

Conclusions:

1. Elderly persons tend to have more change in topographic mapping and affect pattern of corneal topography, due to physiological aging process involve corneal surface curvature, than that in younger population, so there is significant difference with aging.
2. Also gender affect topographic patterns with females highest proportion for most of the patterns
3. The patterns not affected by laterality. By using pentacam (Oculus) for healthy eyes in Iraqi sample of 260 participants found that normal patterns about 75.4% and abnormal patterns about 23.6%, that's to mean 1 out of 4 subjects with healthy eyes have abnormal topographic pattern.

ETHICAL APPROVAL: Al-Qadysia University College of Medicine [AQUCOM] Ethical Committee

CONSENT TO PARTICIPATE: Informed consent was taken from each subject before their enrolment in the study.

HUMAN AND ANIMAL RIGHTS: The study conducted in adherence with Helsinki Ethical standards.

CONSENT FOR PUBLICATION: Authors transfer the copyright to Aalborg Academy Journal of Medical Sciences.

FUNDING: No funding

CONFLICT OF INTEREST: The authors declare no conflict of interest, financial or otherwise.

DATA AVAILABILITY: The data was available in Al-Qadysia University College of Medicine [AQUCOM] set and available on request.

List of abbreviations

AB	Asymmetrical bowtie
AB/SRAX	Asymmetrical bowtie/skewed radial axis
BCVA	Best corrected visual acuity
BUT	Break up time
IOP	Intraocular pressure
IS	Inferior steepening
QS	Quality specification
SB	Symmetrical bowtie
SB/SRAX	Symmetrical bowtie/skewed radial axis
SS	Superior steepening

References

1. Delmont DW, Kim T. Anatomy and physiology of the cornea. *Journal of Cataract & Refractive Surgery*. 2011 Mar 1;37(3):588-98.
2. Wolff's anatomy of the eye and orbit . The cornea and sclera ,8th ed., 1997 : p 233-235.
3. American Academy of Ophthalmology, Basic and Clinical Science Course. Fundamentals and principles of ophthalmology ,2016-2017: p45-47.
4. Rabinowitz YS, Yang H, Brickman Y, Akkina J, Riley C, Rotter JI, Elashoff J. Videokeratography database of normal human corneas. *British journal of ophthalmology*. 1996 Jul 1;80(7):610-6.
5. Bogan SJ, Waring GO, Ibrahim O, Drews C, Curtis L. Classification of normal corneal topography based on computer-assisted videokeratography. *Archives of Ophthalmology*. 1990 Jul 1;108(7):945-9.
6. Brody J, Waller S, Wagoner M. Corneal topography: history, technique, and clinical uses. *International ophthalmology clinics*. 1994 Jul 1;34(3):197-207.
7. Anderson D. Understanding Corneal Topography. *Paraoptometric Resource Center*. 2000;1:1-2.
8. Goss D, Gerstman D. The optical science underlying the quantification of corneal contour. *Indiana J Optom*. 2000;3:13-6.
9. Hashemi H, Mehravaran S. Day to day clinically relevant corneal elevation, thickness, and curvature parameters using the orbiscan II scanning slit topographer and the

- pentacamscheimpflug imaging device. Middle East African journal of ophthalmology. 2010 Jan;17(1):44.
10. Shankar H, Taranath D, Santhirathelagan CT, Pesudovs K. Anterior segment biometry with the Pentacam: comprehensive assessment of repeatability of automated measurements. *Journal of Cataract & Refractive Surgery*. 2008 Jan 1;34(1):103-13.
 11. Oliveira CM, Ribeiro C, Franco S. Corneal imaging with slit-scanning and Scheimpflug imaging techniques. *Clinical and Experimental Optometry*. 2011 Jan;94(1):33-42.
 12. American Academy of Ophthalmology, Basic and Clinical Science Course. *Refractive surgery, 2016-2017*: p28.
 13. Rasheed K, Rabinowitz YS, Remba D, Remba MJ. Interobserver and intraobserver reliability of a classification scheme for corneal topographic patterns. *British journal of ophthalmology*. 1998 Dec 1;82(12):1401-6.
 14. Riley AF, Grupcheva CN, Malik TY, Craig JP, McGhee CN. The Auckland Cataract Study: demographic, corneal topographic and ocular biometric parameters. *Clinical & experimental ophthalmology*. 2001 Dec;29(6):381-6.
 15. Kanpolat A, Simşek T, Alp NM. The evaluation of normal corneal topography in emmetropic eyes with computer-assisted videokeratography. *The CLAO journal: official publication of the Contact Lens Association of Ophthalmologists, Inc*. 1997 Jul; 23(3):168-71.
 16. Kim SJ, Kim DM, Lee JH, Chang BL, Yun DH. Normal corneal topographic patterns of Korean adults. *Journal of the Korean Ophthalmological Society*. 1996 Nov 1; 37(11):1789-95.
 17. Sinjab MM. *Corneal Topography in Clinical Practice (Pentacam System) Basics and Clinical Interpretation*. JP Medical Ltd; 2012 May 18.
 18. Jehangir N, Iqbal S, Ahmad M. Corneal Topography Pattern in Healthy Volunteers Coming to the Ophthalmology Department Hayatabad Medical Complex, Peshawar as Attendants. *Pakistan Journal of Ophthalmology*. 2012 Apr;28(2):81.
 19. Salvi SM, Akhtar S, Currie Z. Ageing changes in the eye. *Postgraduate medical journal*. 2006 Sep 1;82(971):581-7.
 20. Liu Z, Huang AJ, Pflugfelder SC. Evaluation of corneal thickness and topography in normal eyes using the Orbscan corneal topography system. *British journal of ophthalmology*. 1999 Jul 1;83(7):774-8