



## Histopathological Evaluation of Ulcerative Colitis Induced by White Vinegar in Albino Rats

[Hana M. Asrafiel](#)<sup>1</sup>, [Eda M. A. Alshailabi](#)<sup>2\*</sup>, [Fatimah A. Mohammed](#)<sup>2</sup>, [Ahmed S. H. Ahmeedah](#)<sup>3</sup>

<sup>1</sup>Higher institute of medical professions, El Beida, Libya

<sup>2</sup>Zoology Department, Omar Al-Mukhtar University, El Beida, Libya

<sup>3</sup>Tobruk Liver Disease Center, Tobruk, Libya

Corresponding Author: [eda.muftah@omu.edu.ly](mailto:eda.muftah@omu.edu.ly)

**Citation:** Asrafiel HM, Alshailabi EM, Mohammed FA, Ahmeedah AS. Histopathological evaluation of ulcerative colitis induced by white vinegar in albino rats. Al-Kitab J. Pure Sci. 2024; 8(2):23-30. Doi: <https://doi.org/10.32441/kjps.08.02.p3>.

**Keywords:** Ulcerative Colitis, Histopathology, White Vinegar, and Rats.

### Article History

Received	20 Mar.	2024
Accepted	06 May	2024
Available online	09 June	2024

©2024. THIS IS AN OPEN-ACCESS ARTICLE UNDER THE CC BY LICENSE  
<http://creativecommons.org/licenses/by/4.0/>



### Abstract:

Ulcerative colitis (UC) is an inflammatory bowel illness that causes persistent inflammation of the colon's innermost layers. A prominent characteristic of ulcerative colitis (UC) is the stool's blood and mucous contents. This study determined to investigate the effects of white vinegar (WV) on colon tissues in rats. Two groups of twenty rats were created; the primary group was a control, healthy group, and the WV was administered to the second group at a dose of [1 ml/kg (5%)] via oral gavage for two weeks. Findings revealed the emergence of histopathological alterations like mucosal erosions, ulceration, loss of normal architecture, mucosal atrophy, and hemorrhage; numerous crypts have inflammatory cells that entered them, blood vessels are dilated, and edema. The serosa is destroyed, which demonstrates the devastation of the mucosal lining destruction with goblet cell hyperplasia, focal necrosis of epithelium with demolished connective tissues, accumulation of inflammatory cells in the mucosa, lamina propria, and muscularis mucosa, as well as submucosal edema when compared with the control rats. The PAS-reaction histochemical analysis showed that the treated rats had lower levels of carbohydrates than the control animals. The study's findings demonstrated that white vinegar was a dangerous substance linked to histological alterations that resulted in acute ulcerative colitis when used daily for two weeks.

**Keywords:** Ulcerative Colitis, Histopathology, White Vinegar, and Rats.

## تقييم الأمراض النسيجية لالتهاب القولون التقرحي المستحث بالخل الأبيض في الجرذان البيض

هناء محمد اسرافيل<sup>1</sup>، عيدة مفتاح الشيلابي<sup>2\*</sup>، فاطمة العماري محمد<sup>1</sup>، أحمد سعيد أحميده<sup>3</sup>

<sup>1</sup>المعهد العالي للمهن الطبية، البيضاء، ليبيا.

<sup>2</sup> قسم علم الحيوان، جامعة عمر المختار، البيضاء، ليبيا.

<sup>3</sup> مركز طبوق وأمراض الكبد، طبرق، ليبيا.

[mohammedhana1771987@gmail.com](mailto:mohammedhana1771987@gmail.com), [eda.muftah@omu.edu.ly](mailto:eda.muftah@omu.edu.ly), [lafatima.alamari@omu.edu.ly](mailto:lafatima.alamari@omu.edu.ly), [ahmed89\\_said@gmail.com](mailto:ahmed89_said@gmail.com)

### الخلاصة:

التهاب القولون التقرحي (UC) هو مرض التهابي في الأمعاء يسبب التهابًا مستمرًا في الطبقات العميقة للقولون. ومن السمات البارزة لالتهاب القولون التقرحي هو وجود دم ومحتويات مخاطية في البراز. كان الغرض من هذه الدراسة هو دراسة تأثيرات الخل الأبيض على أنسجة القولون في الجرذان البيضاء. تم إنشاء مجموعتين من عشرين جرذ؛ كانت المجموعة الأولى عبارة عن مجموعة ضابطة تتمتع بصحة جيدة، وتم إعطاء المجموعة الثانية جرعة [1 مل/كجم (0.5٪)] من الخل الأبيض عن طريق التجريع بالفم لمدة أسبوعين. كشفت النتائج عن ظهور تغيرات نسيجية مرضية مثل: التآكلات المخاطية، التقرحات، فقدان البنية الطبيعية، ضمور الغشاء المخاطي، النزف، تسلل العديد من الخلايا التهابية، توسع الأوعية الدموية والوذمة، تلف الطبقة المصلية، مما يدل على دمار أنسجة بطانة الغشاء المخاطي، وكذلك وجود تقرح في منتصف الغشاء المخاطي والصفحة الخاصة، أيضا ظهور تقرح أعمق مع نخر ظهاري بؤري وبداية نخر مع تدمير في الأنسجة الضامة، وتجمع الخلايا الالتهابية مع تضخم الخلايا الكأسية، وكذلك الغشاء المخاطي العضلي والوذمة تحت المخاطية مع توسع واحتقان الأوعية الدموية بالمقارنة مع الجرذان الضابطة. أظهر التحليل الكيميائي النسيجي لتفاعل صبغة حمض شيف الدوري أن الجرذان المعاملة بالخل الأبيض لديها مستويات أقل من الكربوهيدرات مقارنة بالحيوانات الضابطة. أظهرت نتائج هذه الدراسة أن الخل الأبيض مادة خطيرة مرتبطة بالتغيرات النسيجية التي أدت إلى التهاب القولون التقرحي الحاد عند استخدامه بشكل يومي لمدة أسبوعين.

**الكلمات المفتاحية:** التهاب القولون التقرحي، الأمراض النسيجية، خل أبيض، الجرذان

### 1. Introduction:

Ulcerative colitis (UC) is one of the forms of inflammatory bowel disease (IBD) and affects mainly the colon and rectum. It is a lingering, recurring, and advanced disease, and no action to date would lead to perpetual therapy. Its commonness has increased in most areas of the world [1]. Among the pathogenic features of UC are increased making of reactive oxygen species (ROS), impaired mucosal integrity, inflammatory cells penetrating the mucosa, and decreased antioxidant capacity of the colon. Furthermore, nuclear factor kappa B (NF- $\kappa$ B), reliant on proinflammatory mediators such as interleukin six and tumour necrosis factor-alpha (TNF- $\alpha$ ), is expressed downstream [2, 3]. UC is the term for a recurrent colon infection that has

symptoms such as nausea, vomiting, diarrhea, and stomach pain [4], ulcers, reduction in body mass, an increase in colon weight, blood in the stool, intestinal wall thickening, decreased mucus production, and inflammation that are commonly observed in this condition [5]. Moreover, in UC, the rectum may also be affected by the large intestine-specific structural alterations and inflammatory response [6]. Besides, the etiology of UC has been frequently linked to decreased antioxidant capacity and elevated generation of free radicals, including ROS [5]. Whereas lipid peroxidation (LPO), brought on by an excess of ROS, might impair cellular antioxidant capability and eventually result in visible inflammation of the colon [7]. Moreover, the high generation of free radicals results in severe oxidative stress (OS), which damages the cell and its membrane [8]. Additionally, the production of ROS, such as hydrogen peroxide, hydroxyl radicals, and superoxide anion, can lead to tissue damage and LPO, particularly in membranes [9].

The unstable biological acid that defines the product as vinegar is called white vinegar (WA). It ranges between around 3 and 10% of the acetic acid concentration and is answerable for the strong, acrid smell of different kinds of vinegar [10]. Furthermore, ingesting WA can cause corrosive harm to the upper gastrointestinal system in certain areas [11]. In addition, the WA causes deep, circular stomach and duodenal ulcers [12]. Likewise, [13] shows that WV affects the gastrointestinal mucosa in rats by causing damage and ulcers. This work determines to examine the effects of WV on colon tissues in albino rats.

## 2. Material and Methods:

**2.1. Chemicals:** White vinegar (WV) was acquired from Omar Al-Mukhtar University, where it was prepared at the Al-Mukhtar Research Center from acetic acid ( $\text{CH}_3\text{COOH}$ ). For two weeks, rats were garaged with 1 ml/kg/b.w./day of white vinegar, where rats were administered 5% of WV, as per [8, 13].

**2.2 Animals:** *Rattus norvegicus* albino rats in good health, weighing between 180 and 225g on average, were employed. Rats were attained from the Zoology Department's Animal House at the University of Omar Al-Mukhtar's Faculty of Science in El-Beida, Libya. To ensure that there were no issues throughout the experiment, all rats were given a three-week lead time to become used to the lab environment. They were kept at room temperature in cages. Rats were given a lab diet and unlimited access to fresh water each day.

### 2.3 Experimental design:

Twenty albino rats, all female, were used. Before the experimental procedures, all rats were given water at their discretion and kept free from food for a whole day. They were then randomly assigned to two groups (n = 10): For a period of two weeks, distilled water was

administered orally to normal control rats, while WV (5%) was administered orally to treated rats via gavage at a rate of 1 ml/kg/b. w./day. Following the end of the treatment session, each rat was fasted for a full day. The colon was removed after the animals were sacrificed.

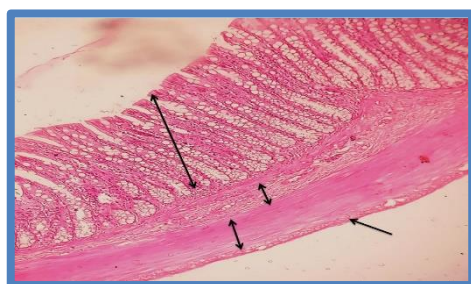#### 2.4 Histological and histochemical investigations:

Following a normal saline wash, colon samples were fixed in buffered formalin (10%) for general histological examination using Hematoxylin and Eosin stain [14]. Periodic acid Schiff's reaction (PAS) stain for carbohydrates was used histochemical [15].

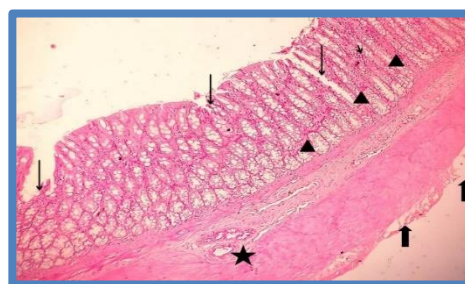
### 3. Results:

The colon tissues in the control rats' slice displayed the typical mucosal layers (the mucosa, submucosa, muscularis externa, and serosa) as well as the typical histological structure in **Figure 1**, while the histological alterations are displayed in **Figure 2**, the rats treated with 5% WA showed mucosal erosions, ulceration, loss of normal architecture, and mucosal atrophy. The mucosa is also haemorrhage. Numerous crypts have inflammatory cells entering them, blood vessels are dilated, and oedema, and the serosa is destroyed. In addition, **Figures 3&4** demonstrate the devastation of the mucosal lining, the ulceration at the midpoint of the mucosa, the lamina propria, deeper ulceration with focalized epithelial necrosis, and the beginning of necrosis with the destruction of connective tissues and aggregation of inflammatory cells with goblet cell hyperplasia, and the muscularis mucosa and submucosal oedema with dilatation and vascular congestion.

The control colon tissues exhibited a strong positive response in the PAS-reacted in the goblet cells and the muscularis mucosa, as well as a high increase in PAS reactive in their tissues **Figure 5**. In contrast to the control group, rats administered with 5% WA demonstrated a noteworthy reduction in the PAS reactive carbohydrate content of goblet cells, muscularis mucosa, and surface cells, as shown in **Figure 6**. Where the extracellular mucus and the mucous layer both had a decrease in color reactivity and did not display the magenta PAS stain type, reflecting the harmful effects of WV.

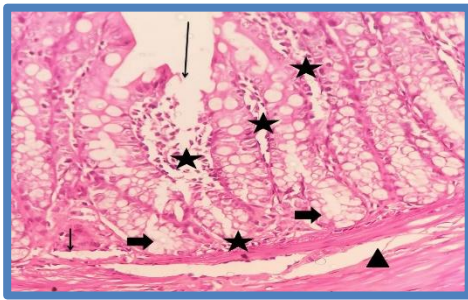


**Figure 1:** The control rat's colon tissue showing normal histological structure and normal mucosal layers (Mucosa, Submucosa, Muscularis externa & serosa) (H& E stain, X100).

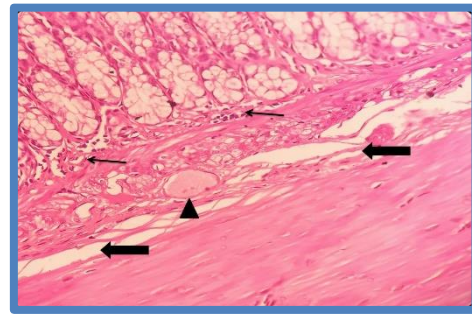


**Figure 2:** The rat's colon tissue treated with WA 5% showed ulcerations, erosions, and atrophy of the mucosa (long arrows). The mucosa is also haemorrhage (head arrows), and certain crypts have inflammatory cells entering them (short arrow), dilated blood vessels with oedema "wall thickening" (star), and destruction of the serosa (H& E stain, X100).





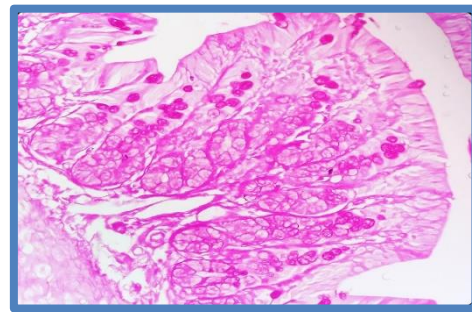
**Figure 3:** The rat's colon tissue treated with WV 5% showing the destruction of the mucosal lining, deeper ulceration with the onset of necrosis, and focal necrosis of epithelium (long arrow) with demolished connective tissues with aggregation of inflammatory cells infiltration in the mucosa, lamina propria with goblet cell hyperplasia (stars), ulceration at the mid part of the mucosa (short arrow), vacuolated or lightly stain cytoplasm (thick arrows), and the muscularis mucosa and submucosal oedema (head arrow) (H& E stain, X400).



**Figure 4:** The rat's colon tissue treated with WV 5% showing inflammatory infiltration cells in the mucosa and lamina propria (arrows), submucosal oedema (thick arrows) with dilatation and vascular congestion (head arrow) (H& E stain, X400).



**Figure 5:** PAS-reacted colon tissue of control rats demonstrating a strong positive response (PAS stain, X400).



**Figure 6:** PAS-reacted colon tissue of rats treated with WV 5% demonstrating a drop in PAS reactive material (PAS stain, X200).

#### 4. Discussion:

The findings of the current study illustrated histological alterations in rats given WV (5%) for two weeks, including mucosal lining destruction with goblet cell hyperplasia, focal necrosis of epithelium with demolished connective tissues, accumulation of inflammatory cells in the mucosa, lamina propria, and muscularis mucosa, as well as submucosal oedema. Deeper ulcerations with necrosis onset are also included. Furthermore, in comparison to the control rats, there was blood vessel congestion, along with signs of damage such as vacuolated or faintly stained cytoplasm, which is in arrangement with [6], who discovered that the treated rats by WV revealed chemical damage to the mucosal epithelium in colon tissues. Also, they said that the damage by WV is associated with epithelial necrosis and oedema that penetrates the gut mucosal layers. Furthermore, [16] showed that in UC, the grade of inflammation designates the participation of numerous layers, counting the mucosa, submucosa, and the whole thickness of the colon barrier, and the harshness of inflammation shows the penetration of inflammatory cells. Also, [1] showed that the damage to the colon caused by WV includes bleeding, reddening, and ulcers. Additionally, in injured UC, the WV stimulates or degrades the mucosa,

increasing the synthesis of several leukotrienes, prostaglandins, and thromboxanes [6]. On the other hand, necrosis, hyperplasia in goblet cells, oedema, and inflammatory cell penetration, according to [17], demonstrated a considerable rise in colon weight and wall thickness. Moreover, WV treatment resulted in significant reductions in colonic and serum malondialdehyde levels as well as glutathione levels, indicating a rise in OS by damage in agreement with [3]. By producing cytotoxic ROS, TNF- $\alpha$  also triggers the synthesis of additional biological mediators, proteases, and proinflammatory indicators. These processes are principal to the penetration and chemotaxis of ulceration, inflammatory cells, and haemorrhage [18, 19]. Furthermore, NF- $\kappa$ B contributes significantly to UC by stimulating the inflammatory mucosae to produce inflammatory mediators, including cyclooxygenase-2 [20]. Free radicals produced by OS increase inflammatory intermediaries and harm colonic mucosa [21]. Similarly, WV results in the breach of the colonic barrier, the permeation of leukocytes into the injured zone, the creation of inflammatory penetration like cytokines and metabolites of arachidonic acid, and the generation of ROS that causes oxidative injury [4]. Consequently, the augmentation of colonic secretions, and contribution to a diversity of digestive ailments, like IBD, are among the pathophysiological changes of WV materials.

On the other hand, the findings demonstrated a significant drop in the PAS-responsive mucosal carbohydrate levels of goblet cells, surface cells, and the muscularis mucosa in rats given a 5% WA treatment in contrast to the control rats. These results were consistent with [22, 13], who found that WV-induced ulcers were linked to a reduction in PAS-response in mucosal cells as an effect of WV's destructive result on mucus cells or extreme OS. This reduction in collagen fiber statement and TNF- $\alpha$  expression at the site of damage may be the cause of these findings. Also, a decline in the goblet cells in the WA rats may be the cause of a drop in PAS-responsive mucosal carbohydrate gratified in colon tissues in the WA rats. Thus, the majority of the cells were either depleted or had little mucus.

## 5. Conclusion:

The results of this investigation presented that white vinegar was a hazardous chemical related to the histological variations that produced acute ulcerative colitis when used daily for two weeks in rats.

## 6. References:

- [1] Adakudugu EA, Ameyaw EO, Obese E, et al. Protective effect of bergapten in acetic acid-induced colitis in rats. *Heliyon*. 2020 Mar;6(8):e04710. <https://doi.org/10.1016/j.heliyon.2020.e04710>.
- [2] Gautam KM, Goel S, Ghatule RR, Singh A, Nath G, Goel RK. Curative effect of Terminalia chebula extract on acetic acid-induced experimental colitis: role of antioxidants, free

- radicals, and acute inflammatory marker. *Inflammopharmacology*. 2013 Oct;21(5):377-383. <https://doi.org/10.1007/s10787-012-0147-3>.
- [3] Rafeeq M, Murad HAS, Abdallah HM, El-Halawany AM. Protective effect of 6-paradol in acetic acid-induced ulcerative colitis in rats. *BMC Complement Med Ther*. 2021 Jan; 21(28):1-10. <https://doi.org/10.1186/s12906-021-03203-7>.
- [4] Abdulaziz MA, Salim SA, Hatem MA, Mohammed SO, Mihir YP, Mohammed MA. Pretreatment of *Gymnema Sylvestre* revealed the protection against acetic acid-induced ulcerative colitis in rats. *BMC Complement Altern Med*. 2014 Feb;14(1):1-11. <https://doi.org/10.1186/1472-6882-14-49>.
- [5] Al-Rejaie SS, Abuhashish HM, Al-Enazi MM, Al-Assaf AH, Parmar MY, Ahmed MM. Protective effect of naringenin on acetic acid-induced ulcerative colitis in rats. *World J Gastroenterol*. 2013 Sep;19(34):5633-5644. <https://doi.org/10.3748/wjg.v19.i34.5633>.
- [6] Bahrami G, Malekshahi H, Miraghaee S, Madani H, Babaei A, Mohammadi B, Hatami R. Protective and therapeutic effects of Aloe Vera gel on ulcerative colitis induced by acetic acid in rats. *Clin Nutr Res*. 2020 Jul;9(3):223-234. <https://doi.org/10.7762/cnr.2020.9.3.223>.
- [7] Tahan G, Aytac E, Aytakin H, Gunduz F, Dogusoy G, Aydin S, Tahan V, Uzun H. Vitamin E has a dual effect of anti-inflammatory and antioxidant activities in acetic acid-induced ulcerative colitis in rats. *Can J Surg*. 2011 Oct;54(5):333-338. <https://doi.org/10.1503/cjs.013610>.
- [8] Alshailabi EMA, Asrafiel HM, Ahmeedah ASH. Evaluation of effects of white vinegar-induced gastric mucosal ulceration in rats. *Global Libyan J*. 2022 Jan;55:1-25.
- [9] Almasaudi SB, Abbas AT, Al-Hindi RR, El-Shitany NA, Abdel-Dayem UA, Ali SS, Saleh RM, Al Jaouni SK, Kamal MA, Harakeh SM. Manuka honey exerts antioxidant and anti-inflammatory activities that promote the healing of acetic acid-induced gastric ulcers in rats. *Evid Based Complement Alternat Med*. 2017 Jan;2017:1-12. <https://doi.org/10.1155/2017/5413917>.
- [10] Mahmoodi M, Hosseini-zijoud S, Hassan SG, Hassanshahi G, Nabati S, Modarresi M, Mehrabian M, Sayyadi A, Hajizadeh M. The effect of white vinegar on some blood biochemical factors in type 2 diabetic patients. *J Diabetes Endocrinol*. 2013 Jan;4(1):1-5. <https://doi.org/10.5897/JDE12.015>.
- [11] Kamijo Y, Soma K, Iwabuchi K, Ohwada T. Massive noninflammatory periportal liver necrosis following concentrated acetic acid ingestion. *Arch Pathol Lab Med*. 2000 Jan; 124(1):127-129. <https://doi.org/10.5858/2000-124-0127-MNPLNF>.
- [12] Gopinathan S, Naveenraj D. Gastroprotective and anti-ulcer activity of Aloe vera juice, Papaya fruit juice and Aloe vera and Papaya fruit combined juice in ethanol-induced ulcerated rats. *Int. J. Drug Dev Res*. 2013 Oct;5(4):300-311.
- [13] Alshailabi EMA, Asrafiel HM, Ahmeedah ASH. Effects of vinegar acid on the duodenum tissues in rats. *Histopathological and histochemical studies. J Applied Sci*. 2022 Apr;8:35-47.
- [14] Harris HF. 1990. After Bruce Cassel man WC. 1959. *Histochemical technique*, by Methuen and Co. Ltd.

- [15] Drury RAV, Wallington EA. Carlton's Histological Techniques (5<sup>th</sup> ed.) Oxford University Press, New York, Toronto, USA. 1980.
- [16] Niu X, Fan T, Li W, Zhang Y, Xing W. Protective effect of sanguinarine against acetic acid-induced ulcerative colitis in mice. *Toxicol Appl Pharmacol.* 2013;267:256-265. <https://doi.org/10.1016/j.taap.2013.01.009>.
- [17] Owusu G, Obiri DD, Ainooson GK, Osafo N, Antwi AO, Duduyemi BM, Ansah C. Acetic acid-induced ulcerative colitis in Sprague Dawley rats is suppressed by hydroethanolic extract of *Cordia vignei* Leaves through reduced serum levels of TNF- $\alpha$  and IL-6. *Int J Chronic Dis.* 2020 Feb; 2020: 8785497. <https://doi.org/10.1155/2020/8785497>.
- [18] Munakata W, Liu Q, Shimoyama T, Sawaya M, Umeda T, Sugawara K. Ecabet sodium attenuates reactive oxygen species produced by neutrophils after priming with bacterial lipopolysaccharides. *Luminescence.* 2003 Nov-Dec;18(6):330–333. <https://doi.org/10.1002/bio.745>.
- [19] Jainu M, Mohan K, Devi C. Protective effect of *Cissus quadrangularis* on neutrophil-mediated tissue injury induced by aspirin in rats. *J Ethnopharmacol.* 2006 Apr;104(6):302–305. <https://doi.org/10.1016/j.jep.2005.08.076>.
- [20] El-Akabawya G, El-Sherifa NM. Zeaxanthin exerts protective effects on acetic acid-induced colitis in rats via modulation of proinflammatory cytokines and oxidative stress. *Biomed Pharmacother.* 2019 Mar;111:841–851. <https://doi.org/10.1016/j.biopha.2019.01.001>.
- [21] Tanideh N, Masoumi S, Hosseinzadeh M, et al. The healing effect of *Pistacia atlantica* fruit oil extract in acetic acid-induced colitis in rats. *Iran J Med Sci.* 2014 Nov;39(6):522-528.
- [22] El-Azab NE, Mansy AE, El-Mahalaway AM, Sabry D. Comparative study of the therapeutic effect of pomegranate alone or in combination with bone marrow mesenchymal stem cells on experimentally induced gastric ulcer in adult male rats: A histological and immunohistochemical study. *Egyptian J Histol.* 2018 Jun;10:150-166. DOI:10.21608/EJH.2018. 13838.